

Use of Topical Sucralfate in the Management of Postoperative Pain After Tonsillectomy

Eurasian Clinical and Analytical Medicine Original Research

Topical Sucralfate and Postoperative Pain After Tonsillectomy

Gül Soylu Özler, Cengiz Arlı, Ertap Akoğlu

Department of Otorhinolaryngology Head and Neck Surgery, Mustafa Kemal University, Hatay, Turkey

Abstract

Aim: The aim of this study is to evaluate the efficacy of sucralfate in terms of pain after tonsillectomy, return to normal diet time and return to regular daily activities time.

Material and Methods: Sixty patients who had undergone cold knife tonsillectomy over 8 years old were randomly divided into two groups, the sucralfate (SUC) group (n=30) and control group (n=30). Patients were evaluated for throat pain, odynophagia and otalgia once a day during the postoperative 7 days. Patients were also followed for return to normal diet time and return to regular daily activities time.

Results: The mean throat pain scores, odynophagia scores and otalgia scores on the operation day and in all seven postoperative days in SUC group were significantly lower than control group ($p<0.05$). The mean return to normal diet time and return to regular daily activity time were significantly later in control group than SUC group ($p=0.0001$).

Discussion: According to this data, topical sucralfate could be recommended as an effective, safe, well tolerated agent in reducing symptoms after tonsillectomy.

Keywords

Tonsillectomy; Postoperative Pain; Pain Scores; Sucralfate

DOI:10.4328/ECAM.33

Received : 29.08.2014

Accepted : 17.09.2014

Published Online : 19.09.2014

Printed Online : 19.09.2014

Eu Clin Anal Med 2014;2(3): 15-8

Corresponding Author: Gül Soylu Özler, Department of Otorhinolaryngology Head and Neck Surgery, Mustafa Kemal University, Hatay, Turkey.

GSM: +90 505 398 07 78 · **P:** +90 326 221 33 23 · **E-Mail:** soylugul@yahoo.com

How to cite this article: Gul Soylu Ozler, Cengiz Arli, Ertap Akoglu. Use of topical sucralfate in the management of postoperative pain after tonsillectomy. Eu Clin Anal Med 2014;2(3): 15-8

Introduction

Tonsillectomy is first described by Celsus in the first century [1]. Tonsillectomy is one of the leading procedures performed in otorhinolaryngology practice [2]. Unfortunately, postoperative pain is the most common and distressing morbidity complicating this surgical procedure. Approximately 20–60% of patients complain about severe pain after tonsillectomy [3].

Patients suffer from throat pain, otalgia, dysphagia that may lead to poor oral intake, dehydration, longer hospital stay, and more need for hospital admission and late return to regular daily activities [4, 5]. All of these results deteriorate the life quality of the patient and increase the hospital charges following this procedure [6].

In these patients, reduction of postoperative pain must be the most important goal of the clinician. There are some drugs used before, during or after the procedure to reduce postoperative pain after tonsillectomy [7-11]. Systemic paracetamol and non steroid antiinflammatory drugs are the most commonly used drugs for analgesia. Systemic or local steroids and local anesthetics may also be used to control postoperative pain.

Sucralfate is an agent used in the treatment of peptic ulcer. It is believed to provide a protective barrier by its tendency to bind to exposed protein of the ulcer [9,10]. Also, there is evidence that sucralfate promotes local production of prostaglandin E2, thus increasing blood flow, mucous production, mitotic activity, and surface migration of cells. In addition, sucralfate binds with growth factors, has angiogenic effects and it promotes mucosal healing process [10,11].

Pain after tonsillectomy is caused by the pharyngeal muscles spasm and inflammation and irritation of nerve endings. It continues until the exposed and inflamed muscles become covered with a regenerated mucous membrane [8,9]. Sucralfate may provide a protective coating on surfaces of pharyngeal muscles and prevent from muscle spasm and irritation of open nerve endings.

This study was designed to evaluate the efficacy of sucralfate in the management of pain after tonsillectomy during the first seven days and in return to normal diet time and return to regular daily activities time.

Material and Methods

Study Design and Study Population

Sixty patients who had undergone cold knife tonsillectomy over 8 years old were included in the study. The patients were randomly divided into two groups, the sucralfate(SUC) group(n=30) and control group(n=30). Tonsillectomy indications were; tonsil infections(recurrent acute tonsillitis, chronic tonsillitis, acute tonsillitis complications – arthritis, nephritis -), chronic tonsillar hypertrophy, snoring and apnea. Patients with mental retardation, hemorrhagic diathesis, systemic diseases, central nervous system diseases, peripheral nerve paralysis were excluded.

All operations were done under general anesthesia by the same surgical team. In surgical procedure; the anterior plica of the tonsil was incised with a blade and tonsil capsule was seen by separating the anterior plica from the tonsil by dissection. Then the tonsil was grasped by the tonsil clamp and dissection was done from superior to inferior pole through the tonsillar area. Tonsil was separated by wire snare lastly. Hemostasis was done with compress, if still a hemorrhagic focus was seen, suturation was performed.

Ethics committee approval was obtained from Mustafa Kemal University(13/02/2014-15) and this prospective study was conducted in adherence to the Declaration of Helsinki. Informed consent was obtained from all adult patients and from the parents of children patients.

Drug administration

Topical sucralfate was administered four times a day for the period of 7 days in the SUC group. Sucralfate suspension was first administered 2–3 h after the operation. Patients were instructed to gargle sucralfate gently and then swallow the drug every 6 h during the next 7 days. No topical treatment was used in the control group. The systemic analgesic usage was standardized. During the postoperative period, patients in both groups received 500 mg of oral paracetamol every 6 h during the next 7 days. Antiemetics were administered in case of postoperative nausea or vomiting.

Posttonsillectomy Pain Follow-up

Patients were assessed for throat pain,odynopaghia and otalgia once a day during the postoperative 7 days using the 10-mm visual analog scale(VAS)(0- no pain; 10-severe pain) [10, 12]. The patients were exterted on the first day of the procedure. They were called for control on the seventh day. They filled VAS at hospital on the first and seventh day while they filled VAS at home on the other days.

Patients were also followed for return to normal diet time and return to regular daily activities time.

Statistical Analysis

Statistical analysis was done by using SPSS (Statistical Package for the Social Sciences) 19.0 Evaluation for Windows. Mann-Whitney U test and Chi-square test was used to evaluate the differences between two groups. Statistical significance was defined as $p < 0.05$.

Results

Thirty patients in SUC group and 30 patients in control group completed the study.

Indications

In SUC group, indications for tonsillectomy were; chronic tonsillitis for 17 patients, apnea for 9 patients, chronic tonsillitis and apnea for 4 patients; in control group, chronic tonsillitis for 19 patients, apnea for 8 patients, chronic tonsillitis and apnea for 3 patients.

Demographic Properties

Mean age in SUC group and control group were 18.76 ± 9.79 , and 19.96 ± 10.90 respectively. Seventeen patients(56.7%) in SUC group and 13 patients (43.3%) in control group were females. There were no significant differences for age and gender among the groups ($p = 0.656$, $p = 0.447$).

Posttonsillectomy Pain Follow-up

The mean throat pain scores on the operation day and in all seven postoperative days in SUC group were significantly lower than control group ($p < 0.05$). The highest throat pain scores for both groups were seen on the operation day and it was 6.03 ± 1.54 for SUC group and 7.20 ± 1.56 for control group (Figure 1).

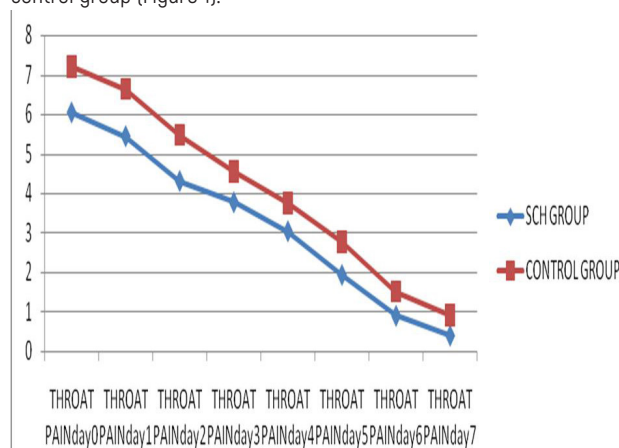


Figure 1. The mean throat pain scores of SUC group and control group on the operation day and in all seven postoperative days

The mean odynophagia scores on the operation day and in all seven postoperative days in SUC group were significantly lower than control group ($p < 0.05$). The highest odynophagia scores for both groups were seen on the operation day and it was 6.43 ± 1.67 for SUC group and 7.36 ± 1.37 for control group (Figure 2).

The mean scores for otalgia scores on the operation day and in all seven postoperative days in SUC group were significantly lower than control group ($p < 0.05$). The highest otalgia scores for both groups were seen on the operation day and it was 2.80 ± 0.80 for SUC group and 3.43 ± 0.67 for control group (Figure 3).

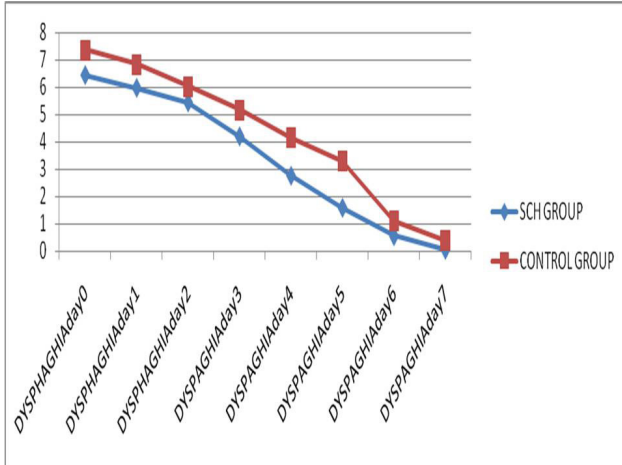


Figure 2. The mean odynophagia scores of SUC group and control group on the operation day and in all seven postoperative days

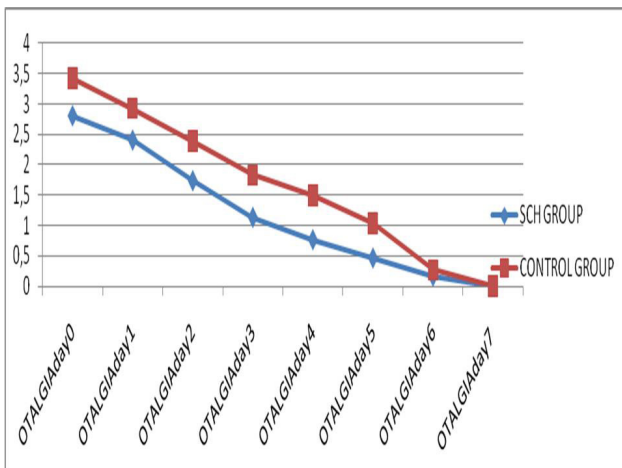


Figure 3. The mean otalgia scores of SUC group and control group on the operation day and in all seven postoperative days

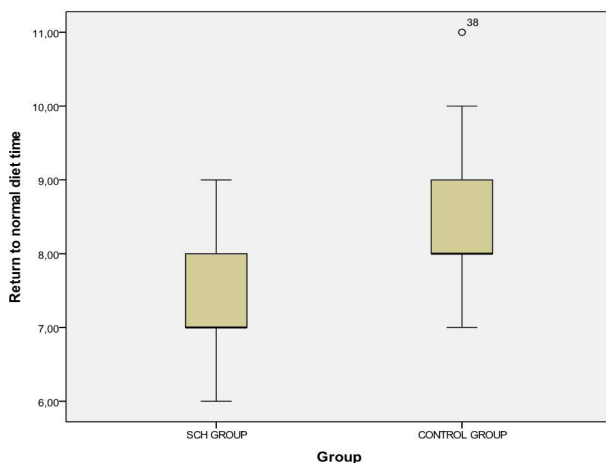


Figure 4. The mean return to normal diet time for SUC group and control group

Return to normal diet time – Return to regular daily activity time The mean return to normal diet time for SUC group and control group were 7.36 ± 0.71 days and 8.53 ± 1.04 days respectively. The mean return to normal diet time were significantly higher in control group than SUC group ($p = 0.0001$) (Figure 4).

Return to regular daily activity time in SUC group and control group were 7.76 ± 0.62 days and 9.03 ± 0.96 days respectively and return to regular daily activity in control group were significantly later ($p = 0.0001$). (Figure 5).

Discussion

Tonsillectomy is an extremely effective procedure in the treatment of upper airway obstruction and recurrent tonsillitis. For this reason it is still the leading operation in ear nose throat practice [12].

Postoperative complications of this procedure includes pain, inadequate oral fluid and food intake, dehydration and secondary bleeding. Pain is mainly located in the throat and ears and tends to be more severe in adults than in children [7-9]. Effective analgesia must be supplied to solve these problems. In addition, the reduction of pain after tonsillectomy improves patients' emotional status and life quality, as well as economic rates [7-11].

No ideal drug to control posttonsillectomy pain has been identified yet. One potential drug in this area could be sucralfate. This drug has cytoprotective properties and has been used treat gastroesophageal reflux, gastritis and peptic ulcers [13]. Sucralfate is also used in the treatment of peristomal erosions, chronic venous ulcers, skin ulcers, burns and recurrent aphthous stomatitis. These biological properties of sucralfate have prompted the use of this drug as a topical agent for the treatment of different types of epithelial wounds, including post-tonsillectomy wounds [10, 14, 15].

There are few studies about the use of sucralfate in morbidity after tonsillectomy and the results of previous studies are controversial [16-20].

In our study we found that throat pain scores, odynophagia scores and otalgia scores on the operation day and in all seven postoperative days in SCH group were significantly lower than control group. In a resembling study conducted by Siupsinskiene et al, they reported lower throat pain scores, odynophagia scores and otalgia scores in patients using topical sucralfate during the postoperative period from initial 3 h after the operation through the 7 days follow-up period [16]. Similarly, Miura et al. reported a significant reduction of throat pain in the sucralfate group during five postoperative days [17]. Sampaio et al. also reported that the use of topical sucralfate had a significant effect on the reduction of throat pain, but they only followed up the pain scores during six initial postoperative hours [9]. Ozcan et al. also reported that patients

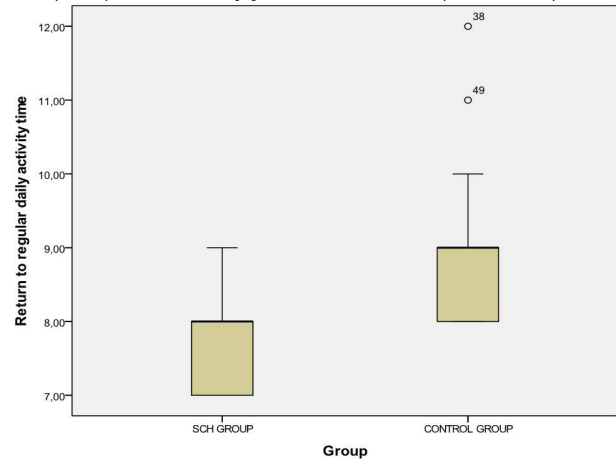


Figure 5. The mean return to regular daily activity time for SUC group and control group

using sucralfate after tonsillectomy had significantly less throat pain during the first three postoperative days, however, they declared no significant effect on otalgia [18]. In contrast, Freeman and Markwell reported that the use of topical sucralfate after tonsillectomy had no significant effect during the ten postoperative days [19].

In this study, we also assessed return to normal diet time and return to regular daily activities time. We found that return to normal diet time and return to regular daily activities time in SCH group were earlier than the control group. There are two other studies evaluated the impact of symptoms after tonsillectomy on oral intake and regular daily activities. Siupsinskiene et al found that the sucralfate group had significantly better scores of well being in general and their return to regular daily activities and oral food and fluid intake was faster [16]. Freeman and Markwell reported that the sucralfate group returned to regular daily activities and normal diet more rapidly than the control group, but the difference in scores was not significant [19].

The most common side effect of sucralfate is constipation. Others are nausea, dry mouth, gastric discomfort, indigestion, rash, pruritus, back pain, allergy, dizziness, drowsiness, vertigo and diarrhoea and are observed very rarely [17, 20].

In our study, we observed no side effects of topical sucralfate.

Limitations of our study is the number of cases we studied. Further larger, more detailed and multi-centred studies are needed to evaluate the effectiveness of topical sucralfate on symptoms after tonsillectomy.

Conclusion

Topical sucralfate could be recommended as an effective, safe, well tolerated agent in reducing symptoms after tonsillectomy.

Scientific Responsibility Statement

The authors declare that they are responsible for the article's scientific content including study design, data collection, analysis and interpretation, writing, some of the main line, or all of the preparation and scientific review of the contents and approval of the final version of the article.

Animal and human rights statement

All procedures performed in this study were in accordance with the ethical standards of the institutional and/or national research committee and with the 1964 Helsinki declaration and its later amendments or comparable ethical standards. No animal or human studies were carried out by the authors for this article.

Funding: None

Conflict of interest

None of the authors received any type of financial support that could be considered potential conflict of interest regarding the manuscript or its submission.

References

- Curtin JM. The history of tonsil and adenoid surgery. *Otolaryngol Clin North Am* 1987;20(2):415-9.
- Nunez DA, Provan J, Crawford M. Postoperative tonsillectomy pain in pediatric patients. *Arch Otolaryngol Head Neck Surg* 2000;126(7): 837-41.
- Paradise JL, Bluestone CD, Colborn DK, Bernard BS, Rockette HE, Kurs-Lasky M. Tonsillectomy and adenotonsillectomy for recurrent throat infection in moderately affected children. *Pediatrics* 2003;110(1):7-15.
- Polites N, Joniau S, Wabnitz D, Fassina R, Smythe C, Varley P, et al. Postoperative pain following tonsillectomy: randomized clinical trial. *ANZ J Surg* 2006;76(4):226-9.
- Schwentner I, Schmutzhard J, Schwentner C, Abraham I, Hofer S, Sprinzl G. The impact of adenotonsillectomy on children's quality of life. *Clin Otolaryngol* 2008;33(1):56-66.
- Nafiu OO, Chimbira WT, Woolford SJ, Tremper KK, Reynolds PI, Green GE. Does high BMI influence hospital charges in children undergoing adenotonsillectomy? *Obesity* 2008;16(7):1667-71.
- Baugh RF, Archer SM, Mitchell RB, et al. American Academy of Otolaryngology-Head and Neck Surgery Foundation. Clinical practice guideline: tonsillectomy in children. *Otolaryngol Head Neck Surg* 2011;144(1):1-30.
- Isaacson G. Tonsillectomy care for the pediatrician. *Pediatrics* 2012;130(2):324-34.
- Sampaio AL, Pinheiro TG, Furtado PL, et al. Evaluation of early postoperative morbidity in pediatric tonsillectomy with the use of sucralfate. *Int J Pediatr Otorhinolaryngol* 2007;71(4):645-51.
- Masuelli L, Tumino G, Turriziani M, et al. Topical use of sucralfate in epithelial wound healing: clinical evidences and molecular mechanisms of action. *Recent Pat Inflamm Allergy Drug Discov* 2010;4(1):25-36.
- Siupsinskiene N, Kaminskaitė K, Dubosas L. Systemic and topical medicine for treatment

of pain after pharyngeal surgery. *Health Sci* 2011;21(7):134-9.

- Younis R.T, Lazar R.H. History and Current Practice of tonsillectomy. *Laryngoscope* 2002;112(1):3-5.
- Tarnawski A, Ahluwalia A, Jones MK. Gastric cytoprotection beyond prostaglandins: cellular and molecular mechanisms of gastroprotective and ulcer healing actions of antacids. *Curr Pharm Des* 2013;19(1):126-32.
- Tumino G, Masuelli L, Bei R, et al. Topical treatment of chronic venous ulcers with sucralfate: a placebo controlled randomized study. *Int J Mol Med* 2008;22(1):17-23.
- Altenburg A, Abdel-Naser MB, Seeber H, et al. Practical aspects of management of recurrent aphthous stomatitis. *JEADV* 2007;21(8):1019-26.
- Siupsinskiene N, Zekoniene J, Padervinskis E, Zekonis G, Vaitkus S. Efficacy of sucralfate for the treatment of post-tonsillectomy symptoms. *Eur Arch Otorhinolaryngol* 2014. DOI: 10.1007/s00405-014-3023-5.
- Miura MS, Saleh C, de Andrade M, Assmann M, Ayres M, Lubianca Neto JF. Topical sucralfate in post-adenotonsillectomy analgesia in children: a double blind randomized clinical trial. *Otolaryngol Head Neck Surg* 2009;141(3):322-8.
- Ozcan M, Altuntaş A, Unal A, Nalça Y, Aslan A. Sucralfate for posttonsillectomy analgesia. *Otolaryngol Head Neck Surg* 1998;119(6):700-4.
- Freeman SB, Markwell JK. Sucralfate in alleviating posttonsillectomy pain. *Laryngoscope* 1992;102(11):1242-6.
- Zodpe P, Cho JG, Kang HJ, Hwang SJ, Lee HM. Efficacy of sucralfate in the postoperative management of uvulopalatopharyngoplasty: a double-blind, randomized, controlled study. *Arch Otolaryngol Head Neck Surg* 2006;132(10):1082-5.